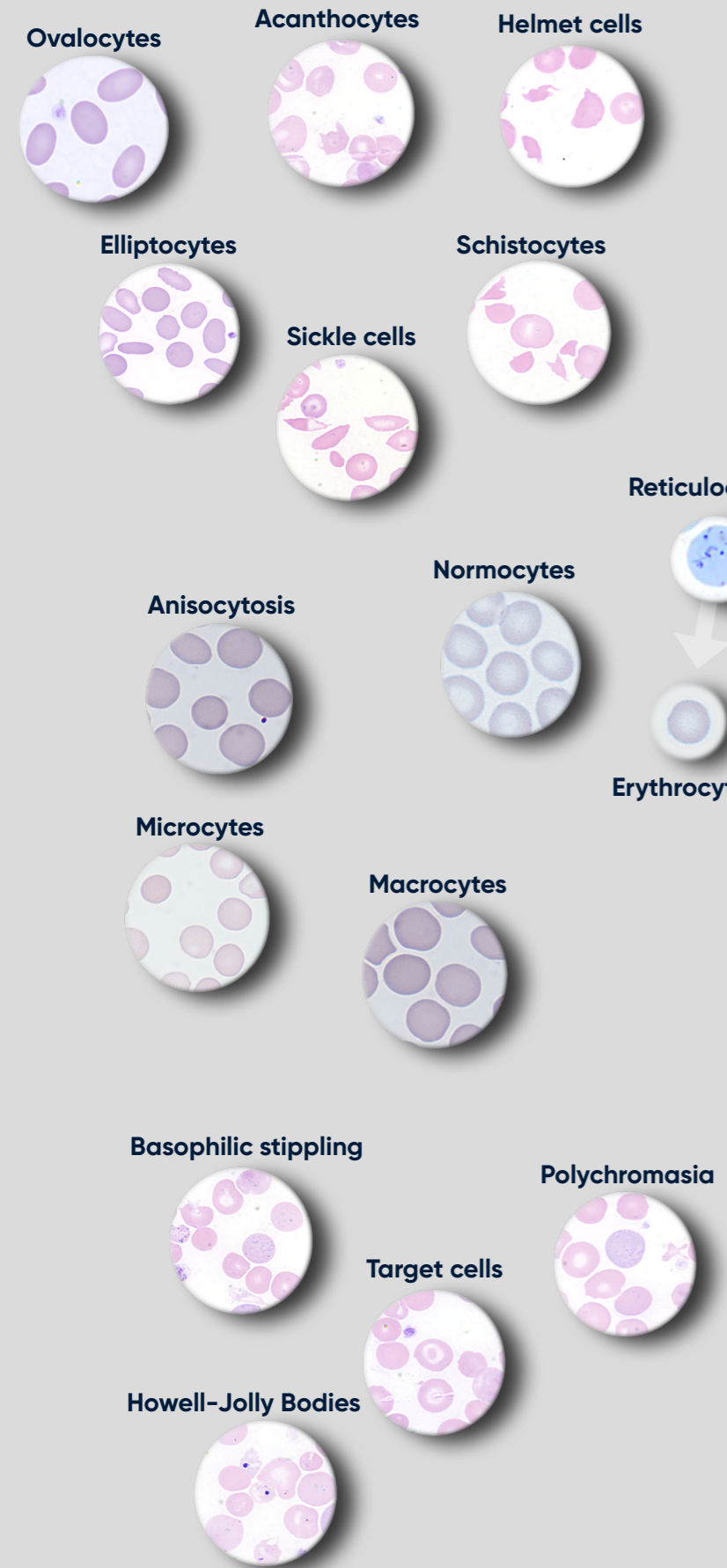


Abnormal erythropoiesis



boule.com

©2018-2026 Boule Diagnostics AB
 Boule Diagnostics AB, Fagerstagatan 7, SE-163 53 Spånga, Sweden
 Cell images by Sigvard Söderström and Helene Johansson, Örebro University Hospital, Sweden
 PO40482-3 02/2026

Normal hematopoiesis

